



Contents lists available at ScienceDirect

North American Spine Society Journal (NASSJ)

journal homepage: www.elsevier.com/locate/xnsj

Clinical Studies

Vancomycin-impregnated calcium sulfate beads compared with vancomycin powder in adult spinal deformity patients undergoing thoracolumbar fusion

Grace Xiong^a, Harold Fogel^b, Daniel Tobert^b, Thomas Cha^b, Joseph Schwab^b, Christopher Bono^b, Stuart Hershman^{b,*}

^a Harvard Combined Orthopaedic Residency Program, Boston, MA, United States

^b Spine Surgery and Complex Spinal Reconstruction, Massachusetts General Hospital, Harvard Medical School, Dept of Orthopaedic Surgery, Yawkey 3A, 55 Fruit St., Boston, MA 02114, United States



ARTICLE INFO

Keywords:

Infection
Calcium sulfate
Thoracolumbar deformity

ABSTRACT

Introduction: Adult spinal deformity (ASD) surgery patients are at higher risk for surgical site infections (SSIs) due to large incisions, high blood loss, long surgical duration, and extensive instrumentation. The use of vancomycin powder has demonstrated inconsistent results in ASD surgery. Antibiotic-impregnated calcium sulfate beads have been used in arthroplasty and foot and ankle surgery with promising results. The purpose of this study was to provide preliminary data on the use of vancomycin-impregnated calcium sulfate beads in the prevention of SSI following ASD surgery and provide comparisons to the use of vancomycin powder.

Methods: A retrospective chart review was performed for 95 consecutive surgical ASD patients at a tertiary care center from January 2017 until March 2020. Patients received either vancomycin powder (powder group) or vancomycin-impregnated calcium sulfate beads (bead group) intrawound prior to closure. Patient demographics, operative course, and incidence of postoperative infections were recorded. A two-tailed chi-squared test was performed to compare infection rates.

Results: Ninety-five patients were included for review. Forty-two patients were in the powder group and 53 patients were in the bead group. The bead group was older (59.8 vs 67.8 years, $p < 0.01$) with similar BMI and rates of diabetes, smoking, and length of surgery. There were four postoperative SSI in the powder group requiring operative irrigation and debridement and one SSI in the bead group (9.5% vs 1.9%, $p = 0.09$). All infections occurred in the first 90 days of the postoperative period.

Conclusion: Preliminary examination of the use of vancomycin-impregnated calcium sulfate beads demonstrated a 1.9% surgical site infection rate in adult spinal deformity surgical patients, which was not significantly different compared with the 9.5% infection rate in patients who received vancomycin powder. Prospective study is needed to determine if the differences found are significant in a larger number of patients.

Introduction

Surgical site infections (SSIs) constitute a significant morbidity and financial burden on patients and healthcare systems. Adult spinal deformity (ASD) patients are at high risk for SSI due to the large incisions, high blood loss, long duration of surgery, and use of extensive multi-level instrumentation [1,2]. The risk of SSI is estimated to be 4–6% [3–5] in this population and significantly increases patient morbidity and cost of care [6]. Routine use of pre-incision intravenous antibiotics is effective but has limitations in achieving required concentrations in subdermal fat tissues [7].

In an attempt to address this gap, the use of vancomycin powder as an intrawound prophylaxis has gained popularity [8,9]. Studies, however, have demonstrated inconsistent results [10]. One potential explanation is the rapid disappearance of clinically relevant antibiotic levels within the wound. Sweet et al. sampled vancomycin levels in wounds that had intraoperative vancomycin powder from postoperative day 0 to postoperative day 3 and found a rapid decline from 1457 ug/mL to 128 ug/mL during this time period [8].

The use of antibiotic-impregnated calcium sulfate beads has been reported in the arthroplasty and foot and ankle literature for the treatment of peri-prosthetic infections [11,12]. This option may be preferable

* Corresponding author.

E-mail address: shershman@mgh.harvard.edu (S. Hershman).

<https://doi.org/10.1016/j.xnsj.2020.100048>

Received 1 December 2020; Received in revised form 16 December 2020; Accepted 23 December 2020

Available online 31 December 2020

2666-5484/© 2020 North American Spine Society. Published by Elsevier Ltd. This is an open access article under the CC BY-NC-ND license

(<http://creativecommons.org/licenses/by-nc-nd/4.0/>)

to antibiotic-impregnated beads composed of polymethylmethacrylate compounds, as calcium sulfate beads do not require subsequent surgical removal [13,14]. Furthermore, studies of vancomycin-impregnated calcium sulfate beads have demonstrated *in vitro* levels above 1000 ug/mL as far as 35 days out from surgery [15], and *in vivo* levels above the minimum inhibitory concentration (MIC) for as long as three months postoperatively [16].

The use of beads for SSI prophylaxis has not been previously reported in the spine literature. The present study describes the use of vancomycin-impregnated calcium sulfate beads for SSI prophylaxis in ASD patients undergoing corrective surgery and compares the infection rates with the use of vancomycin powder.

Methods

Study design and patient selection

Following institutional review board approval, a retrospective analysis was performed of all patients who underwent thoracolumbar fusion for adult spinal deformity with a single surgeon between January 2017 and March 2020. Inclusion criteria were thoracolumbar fusions performed primarily for deformity correction of sagittal or coronal plane imbalance, whether primary or revision surgery. Spinal deformity was defined by the criteria set forth by the Scoliosis Research Society's Adult Spinal Deformity Committee [17]. Exclusion criteria included any fusion done for a diagnosis other than adult spinal deformity. Chart review was undertaken to extract patient demographic data, surgical indications, perioperative data such as length of surgery and estimated blood loss, and postoperative clinical course including time to a surgical site infection, if any, incidence of postoperative seromas, and the incidence of acute kidney injury (AKI) within the first 30 days after surgery.

Use of intraoperative vancomycin powder (powder group) or calcium sulfate beads (bead group, Fig. 1) were confirmed by review of the operative report and medication record. The use of vancomycin powder was exchanged for calcium sulfate beads in October 2018 in an effort to further decrease infection rates. There was no financial or commercial conflict involved in this practice change. For patients who had multiple surgeries during the study period, only the last surgery was included to maintain statistical independence. The Centers for Disease Control (CDC) definition of a deep surgical site infection (SSI) [18] was used to define an infection. Namely, any surgical site infection that involved fascia or deeper, with an incision that 1) had purulent drainage or 2) spontaneously or was surgically opened with positive deep tissue cultures, or 3) had an underlying abscess. The CDC definition stipulates that for spinal fusions, only infections occurring within the first 90 days after surgery are considered deep surgical site infections. For the present study, all infections were recorded, as well as the time from surgery to incidence of infection.

Standard vancomycin delivery regimen

All patients received standard systemic antibiotic prophylaxis consisting of IV cefazolin within one hour of incision followed by 2 gs of IV cefazolin every 8 h for 24 h postoperatively. Intravenous vancomycin was given if patients had a pre-operative nasal swab which was positive for MRSA. Clindamycin was used in cases of cephalosporin allergies.

In the vancomycin powder group (January 2017 to September 2018), 1 gram of vancomycin powder was applied into the deep wound bed prior to closure. In the vancomycin calcium sulfate bead group (October 2018 to March 2020), 1–2 gs of vancomycin was mixed at the time of surgery on a sterile surgical table with 10 or 20cc of calcium sulfate beads respectively, which were in turn applied to the deep wound bed before closure. The calcium sulfate bead volume was determined intraoperatively based on the size of the surgical field with 10cc used in cases where the upper instrumented vertebra (UIV) was in the distal thoracic

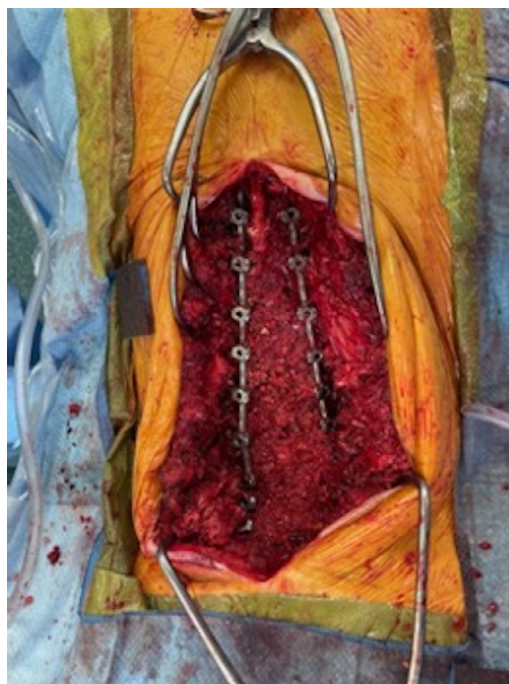


Fig. 1. Intraoperative clinical photos of vancomycin-impregnated calcium sulfate bead subfascial bead placement. A. Surgical site prior to bead placement. B. Surgical site following bead placement.

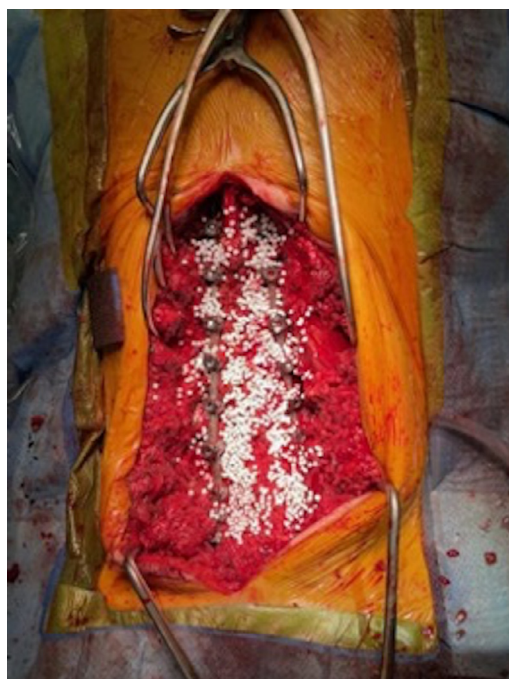

Fig. 1. Continued

spine, and 20cc used in cases where the UIV was in the upper thoracic spine.

Statistical analysis

Primary outcome was the incidence of surgical site infection. Univariate analysis was achieved with Wilcoxon rank sum testing for non-parametric comparisons of means. Two-tailed chi-square testing was used to compare proportions, with binomial logistic regression

Table 1
Patient demographics.

	Group						p-values
	Powder Group (n = 42)		Bead Group (n = 53)		Total		
	Mean/Freq	%/SE	Mean/Freq	%/SE	Mean/Freq	%/SE	
Age (years)	59.83	2.00	67.89	1.12	64.33	1.15	0.002*
BMI (kg/m²)	28.98	0.95	29.15	0.86	29.07	0.63	0.79
Gender							0.26
Female (n = 62)	30	71.4	32	60.4	62	65.3	
Male (n = 33)	12	28.6	21	39.6	33	34.7	
Total (n = 95)	42	100.0	53	100.0	95	100.0	
ASA Class							0.58
I (n = 1)	1	2.4	0	0.0	1	1.1	
II (n = 37)	18	42.9	19	35.8	37	38.9	
III (n = 55)	22	52.4	33	62.3	55	57.9	
IV (n = 2)	1	2.4	1	1.9	2	2.1	
Total (n = 95)	42	100.0	53	100.0	95	100.0	
Diabetes							0.28
Non-diabetic (n = 87)	37	88.1	50	94.3	87	91.6	
Diabetic (n = 8)	5	11.9	3	5.7	8	8.4	
Total (n = 95)	42	100.0	53	100.0	95	100.0	
Smoking Status							0.45
Non-smoker (n = 43)	19	46.3	24	45.3	43	45.7	
Current Smoker (n = 2)	0	0.0	2	3.8	2	2.1	
Former Smoker (n = 49)	22	53.7	27	50.9	49	52.1	
Total (n = 94)	41	100.0	53	100.0	94	100.0	
Estimated blood loss (cc)	1023.6	144.3	1099.5	140.9	1065.9	100.8	0.86
Length of surgery (minutes)	410.8	21.6	382.9	15.0	395.3	12.7	0.29
Number of levels	9.1	0.6	11.3	0.6	10.3	0.5	0.03*
Revision Status							0.34
Primary (n = 25)	22	30.6	3	13.0	25	26.3	
Revision (n = 70)	50	69.4	20	87.0	70	73.7	
Total (n = 95)	72	100.0	23	100.0	95	100.0	
Osteotomy							0.12
No Osteotomy (n = 56)	49	68.1	7	30.4	56	58.9	
Osteotomy (n = 39)	23	31.9	16	69.6	39	41.1	
Total (n = 95)	72	100.0	23	100.0	95	100.0	
Durotomy							0.69
No durotomy (n = 72)	31	73.8	41	77.4	72	75.8	
Durotomy (n = 23)	11	26.2	12	22.6	23	24.2	
Total (n = 95)	42	100.0	53	100.0	95	100.0	

BMI = body mass index, ASA = American Society of Anaesthesiologists score, Cc = cubic centimeters. P-values rounded to two decimal points unless $p < 0.05$. Missing values for smoking were $n = 1$ (1%). No values were missing for age, BMI, gender, ASA class, diabetes, estimated blood loss, length of surgery, revision status, osteotomy, number of levels, or durotomy.

* p-value less than 0.05.

modeling to assess for odds ratios. Due to the low number of infection cases multivariable analysis was precluded, as standard statistical practice necessitates at least ten events per predictor model (EPP) for multivariable analysis [19]. A p-value of < 0.05 was determined a priori as denoting statistical significance and all odds ratios reported with 95% confidence intervals. Statistical analysis was performed using Stata (StataCorp, College Station, TX). Power analysis was performed using the PS: Power and Sample Size Calculation platform (Department of Biostatistics, Vanderbilt University, Nashville, TN).

Results

Demographics

Of the 95 patients included in the study, 33 (34.7%) were male with a mean age of 64.33 years. Patients predominantly had an American Society of Anesthesiologists (ASA) class III ($n = 55$, 57.9%). Eight (8.4%) patients were diabetic and 49 (52.1%) were former smokers. The patients did not differ in any category except that the bead group was older (59.8 vs 67.8 years, $p < 0.01$).

In terms of perioperative course, there were no differences in estimated blood loss, length of surgery, performance of an osteotomy, or incidence of durotomy. The bead group had significantly higher number of levels operated on (11.3 versus 9.1, $p = 0.03$). Full demographics

and intraoperative details are in Table 1. There were two instances of postoperative AKI in the powder group and one in the bead group in the first thirty days after surgery. All these patients received only standard perioperative antibiotics, and all episodes of AKI resolved as documented by creatinine level return to baseline within three days. Within the bead group, the patient who sustained AKI had baseline chronic kidney disease, stage III, with a baseline creatinine of 1.9 mg/dL and 2.56 mg/dL on postoperative day three. This patient received 4 gs of intravenous vancomycin as standard perioperative prophylactic antibiotics in addition to 2 gs of vancomycin via calcium sulfate beads. No serum vancomycin levels are available.

Incidence of infection

Five patients had postoperative surgical site infections, four in the powder group (9.5%) and one in the bead group (1.9%, $p = 0.09$). The five postoperative spine infections varied in terms of pathogen, with three *Klebsiella pneumoniae* and one each of *Staphylococcus aureus*, *Staph epidermidis*, and *Pseudomonas aeruginosa* infections (table 2). Two cases were revision cases, both in the powder group. One patient notably had a significant prior infectious history with periprosthetic joint infection of the knee, although the pathogen in the knee was *Staph epidermidis* in contrast with the pathogen in the spinal surgical site infection which yielded *Pseudomonas aeruginosa*. With regards to CDC criteria, there were no

Table 2
Characteristics of patients who had surgical site infections.

Age/ Gender	Vancomycin Delivery	Diagnosis	Surgery	Infection onset (days)	Tobacco Use	Diabetes	BMI (kg/m ²)	Cultures	Notable issues
40F	Powder	Sagittal imbalance	Revision PSF T11-pelvis; PCO L5	71	Never	None	30.9	<i>Staphylococcus epidermidis</i>	Prior fusion
59M	Powder	Degenerative scoliosis	PSF T10-pelvis	17	Former	None	33.7	<i>Staphylococcus aureus; Klebsiella pneumoniae</i>	Crohn's disease
69M	Powder	Sagittal imbalance	Revision PSF T9-pelvis; PSO L3	20	Never	Non-insulin dependent diabetes	28.3	<i>Klebsiella pneumoniae</i>	Prior fusion; ankylosing spondylitis, AV block with pacemaker
69F	Powder	Flat back syndrome	PSF L2-S1	58	Never	None	31.9	<i>Pseudomonas aeruginosa</i>	Total knee arthroplasty prior periprosthetic joint infection with <i>Staph epidermidis</i>
73M	Bead	Sagittal imbalance	PSF T10-pelvis; laminectomy T10/11	20	Former	Non-insulin dependent diabetes	43.9	<i>Klebsiella pneumoniae</i>	None

PSF - posterior spinal fusion; PCO - posterior column osteotomy, PSO - pedicle subtraction osteotomy.

Table 3
Characteristics of non-infected and infected patients.

	Infection Status						OR [95% CI]	p-value
	Non-infected		Infected		Total			
	No.	%	No.	%	No.	%		
Age (years)	64.46	1.18	62	5.97	64.33	1.15		0.83
BMI (kg/m²)	28.81	0.64	33.74	2.69	29.07	0.63		0.07
Gender								
Female (n = 62)	60	66.7	2	40.0	62	65.3	Ref	Ref
Male (n = 33)	30	33.3	3	60.0	33	34.7	3.00 [0.48 - 18.93]	0.24
Total (n = 95)	90	100.0	5	100.0	95	100.0		
ASA Class								
I (n = 1)	1	1.1	0	0.0	1	1.1	-	-
II (n = 37)	35	38.9	2	40.0	37	38.9	0.99 [0.15 - 6.24]	0.99
III (n = 55)	52	57.8	3	60.0	55	57.9	-	-
IV (n = 2)	2	2.2	0	0.0	2	2.1	-	-
Total (n = 95)	90	100.0	5	100.0	95	100.0		
Diabetes								
Non-diabetic (n = 87)	84	93.3	3	60.0	87	91.6	Ref	Ref
Diabetic (n = 8)	6	6.7	2	40.0	8	8.4	9.33 [1.30 - 67.03]	0.026*
Total (n = 95)	90	100.0	5	100.0	95	100.0		
Smoking Status								
Non-smoker (n = 43)	40	44.9	3	60.0	43	45.7	Ref	Ref
Current Smoker (n = 2)	2	2.2	0	0.0	2	2.1	-	-
Former Smoker (n = 49)	47	52.8	2	40.0	49	52.1	0.56 [0.09 - 3.57]	0.55
Total (n = 94)	89	100.0	5	100.0	94	100.0		
Estimated blood loss (cc)	1079.6	106.1	820	115.8	1065.9	100.8		0.85
Length of surgery (minutes)	389.4	12.8	500	59.6	395.3	12.7		0.09
Number of levels	10.5	0.5	8.0	1.0	10.3	0.5		0.33
Revision Status								
Primary (n = 25)	23	25.6	2	40.0	25	26.3	Ref	Ref
Revision (n = 70)	67	74.4	3	60.0	70	73.7	0.51 [0.08 - 3.28]	0.48
Total (n = 95)	90	100.0	5	100.0	95	100.0		
Osteotomy								
No Osteotomy (n = 56)	54	60.0	2	40.0	56	58.9	Ref	Ref
Osteotomy (n = 39)	36	40.0	3	60.0	39	41.1	2.25 [0.36 - 14.14]	0.39
Total (n = 95)	90	100.0	5	100.0	95	100.0		
Durotomy								
No durotomy (n = 72)	69	76.7	3	60.0	72	75.8	Ref	Ref
Durotomy (n = 23)	21	23.3	2	40.0	23	24.2	2.19 [0.34 - 13.99]	0.41
Total (n = 95)	90	100.0	5	100.0	95	100.0		

*p -value less than 0.05.

patients who had purulent drainage (option 1) or an abscess (option 3) and did not go subsequent operative irrigation and debridement.

Statistical comparisons are detailed in Table 3. Univariate analysis demonstrated that the overall incidence of infection was significantly associated with diabetes (odds ratio 9.3, 95% confidence interval 1.30 – 67.03, $p = 0.026$). There was no significant difference be-

tween infected and non-infected patients in terms of length of surgery (389.4 min non-infected, 500 min infected, $p = 0.09$). There was a non-significant trend towards higher BMI in the infection group (28.8 versus 33.7 kg/m², $p = 0.07$). The incidence of infection was not associated with gender, smoking status, age, ASA status, or estimated blood loss.

There were no reported seromas in either group. Mean followup was longer in the powder group (748 +/- 43 days) compared with the bead group (285 +/- 21 days, $p < 0.001$). All reported infections occurred in the first 90 days after surgery (powder group mean 37.6 +/- 11 days, bead group 20 days), in keeping with CDC criteria.

Power analysis demonstrated that, assuming a type I error probability of 0.05, with a calculated odds ratio of infection among the bead group compared with the powder group to be 0.18, that the power was 0.39.

Discussion

From these data, intraoperative vancomycin impregnated calcium sulfate beads may be a viable alternative to vancomycin powder application after ASD surgery. Prior literature specific to the adult spinal deformity population has found varying results with the use of vancomycin powder, some of which have demonstrated lower rates of SSI with vancomycin powder [8,20] and some which have not [10,21]. Theologis et al. retrospectively reviewed 64 patients undergoing thoracolumbar deformity surgery who received routine IV antibiotics versus 151 patients who received both IV antibiotics and vancomycin powder and found significantly decreased rates in the vancomycin powder group (10.9% versus 2.6%, $p = 0.01$) [9]. Martin et al., on the other hand, found no difference in surgical site infections in 306 patients undergoing thoracolumbar fusion for deformity surgery with or without the use of intraoperative vancomycin powder (5.1% with, 5.3% without, $p = 0.93$) [10].

The current study did not find a statistically significant difference in infection rate between the groups using vancomycin-impregnated calcium sulfated beads compared with powder beads. The incidence of infections (9.5% for the powder group and 1.9% for the bead group), makes powering such a study difficult. Hence while the differences did not reach statistical significance, the percentage change of the infection rate by 7.6% suggests that the use of antibiotic calcium beads merits further study. Furthermore, the cohort in the present study was largely comprised of patients meeting ASA class III, likely secondary to the overall medical complexity of patients at a tertiary referral center. It is possible that healthier patients would experience lower infection rates. The higher odds of infection in diabetics in the current study (OR 9.3, $p = 0.026$) is in keeping with findings in the prior literature [1,3].

To our knowledge, this study is the first to use antibiotic impregnated calcium sulfate beads for prophylaxis of infection in spine surgery patients. Previous literature has proposed several advantages to calcium sulfate delivery as opposed to more traditional methods of direct wound application: 1) biofilm reduction [22,23], slower elution [24], and dead space reduction [25,26].

There have been two prior studies examining the use of antibiotic impregnated calcium sulfate beads in spine surgery, both of which have focused on using the beads for treatment rather than prophylaxis. One prior study by Fleege et al. [27] was performed in 20 patients with spondylodiscitis and found that the addition of antibiotic impregnated calcium sulfate hydroxyapatite pellets allowed the overall parenteral antibiotic duration to be decreased to three weeks without significant decrement in infection. Stechow et al. [28] similarly examined vancomycin impregnated calcium sulfate and hydroxyapatite for spondylodiscitis patients and found no recurrent infection. Both of these studies, however, examined calcium sulfate in addition to hydroxyapatite, which adds a non-resorbable factor [29]. Furthermore, both studies examined using vancomycin impregnated calcium sulfate in spondylodiscitis patients as opposed to infection prophylaxis.

Prior literature in other surgical disciplines has demonstrated increased efficacy when antibiotic is delivered via calcium sulfate or similar compounds as opposed to using antibiotics alone. Marczak et al. (2016) [11] studied 56 patients undergoing second stage revision total knee arthroplasty for periprosthetic joint infection and found a significantly lower reinfection risk in one group receiving antibiotic calcium

sulfate and carbonate beads and parenteral antibiotics ($n = 28$) versus another group receiving parenteral antibiotics alone ($n = 28$, $p = 0.025$).

With regards to use of antibiotic impregnated calcium sulfate beads for prophylaxis as opposed to treatment, Kenna et al. (2018) [30] compared 127 breast reconstructions with tissue expanders with intraoperative antibiotic irrigation and parenteral irrigation, and found a significantly decreased rate of surgical site infection after the protocol was changed to include vancomycin and gentamicin impregnated calcium sulfate beads (11.9% vs 1.5%, $p = 0.02$). Some of the benefit may be derived from dead space management in addition to antimicrobial activity, as other studies have compared bioactive glass to antibiotic impregnated calcium compounds and found comparable results in the treatment of chronic osteomyelitis [31,32].

Conversely, some studies have not shown benefit from antibiotic impregnated calcium sulfate use. Flierl et al. (2017) [33] examined 32 patients undergoing irrigation and debridement for periprosthetic joint infection with the addition of antibiotic-impregnated calcium sulfate beads and found a 48% failure rate. Yarboro et al. (2007) [12] used a rat model of quadriceps *Staphylococcus aureus* infection to compare parenteral, local, and calcium-sulfate loaded with gentamicin and found comparable bacterial counts in rats treated with parenteral versus calcium sulfate carrying gentamicin. These studies were focused on the treatment of infection rather than surgical prophylaxis which represents a different substrate compared with the study population.

ASD patients represent a unique patient population in comparison with other orthopedic use since obtaining a solid fusion is critical to the long-term success of the operation. The use of vancomycin-impregnated calcium sulfate beads has shown promising results in procedures requiring bone formation or fusion. Previous studies have demonstrated that bone regeneration around resorbed calcium sulfate is indistinguishable on histology from autograft in a canine model [34].

In the oral maxillofacial literature, Sun et al. (2016) [35] implanted 12 patients with vancomycin-impregnated calcium sulfate into patients with significant defects after jaw osteomyelitis debridement. At three months they found that the calcium sulfate implants had been largely replaced with bone formation without recurrence of infection. Boyle et al. (2019) [36] compared vancomycin impregnated in both PMMA and calcium sulfate in the treatment of osteomyelitis induced in 64 rats and found no difference in groups; however, a higher bone volume fraction, bone area, and cartilage area was seen in the calcium sulfate group. Similarly, Chang et al. (2007) [37] compared 22 patients with chronic osteomyelitis treated with debridement and 17 with debridement and calcium sulfate placement to fill the void; they found a higher, although not statistically significant, rate of healing in the calcium sulfate group (94% versus 59%, $p < 0.05$). The present study examined the incidence of early postoperative surgical site infections, and further study is needed to determine if fusion rates are affected by antibiotic impregnated calcium sulfate.

Calcium sulfate, while demonstrating favorable use in most studies, has some drawbacks. Hypercalcemia is a rare but reported side effect [38]. Toxic serum levels have also been reported when used with aminoglycosides [39,40] as opposed to vancomycin [16]. Furthermore, calcium sulfate use has been associated with aseptic seroma and wound drainage issues [13,41]. With regards to vancomycin-induced nephrotoxicity, previous orthopedic literature has not shown significant risk for renal injury with vancomycin powder [42-44] or vancomycin-impregnated calcium sulfate [16]. While these were not reported in the present study, further examination and vigilance is needed for these issues in the continued use of calcium sulfate adjuncts.

There were several limitations to the present study. First, the study was a single surgeon retrospective design, limiting generalizability. Second, the study design of consecutive protocols rather than simultaneous comparative cohorts allows for potential confounders. The goal of the present study was to examine early postoperative surgical site infections; however, further study is needed to elucidate the effects on long-term outcomes and fusion rates. Third, although the consecutive nature of

the study protocol could result in lead time bias, prior literature demonstrates that the majority of complications, particularly infection, in adult spinal deformity patients occur within the first 90 days of the postoperative period. This is in keeping with the current study in which all infections occurred in the first three months after surgery as well as CDC definitions of postoperative deep surgical site infection for spinal fusion [18,45]. For the purposes of this study, only deep SSI were examined given the purported relevance to the deep location of the vancomycin powder or beads; however, study of superficial SSI can be considered as well. Finally, perhaps the most significant limitation of the present study was its statistical power limiting the ability to perform multivariable analysis and draw final conclusions regarding differences in infection rates. For example, the proportion of patients who were undergoing a revision as opposed to primary procedure did not differ between the bead and the powder group. Prior literature has demonstrated increased infection risk in revision cases [46] and it is not known what effects this may have had on the present study. The study did not have sufficient events per predictor for multivariable analysis; however, given the low incidence of infection in the bead group, the present study still poses a valuable preliminary look into a novel use of antibiotic calcium sulfate beads for spine surgery and aids in the planning of future studies, notably the large sample size and potential need for multicenter involvement to achieve statistical significance.

Conclusions

Vancomycin powder has gained popularity for surgical site infection prophylaxis in adult spinal deformity surgery. The use of vancomycin-impregnated calcium sulfate beads offers an alternative that provides a more favorable elution profile and removes the need for foreign substance removal. The present study provides preliminary data that vancomycin-impregnated calcium sulfate beads trends towards lower rates of site infection than vancomycin powder in patients undergoing thoracolumbar fusion for adult spinal deformity.

Declaration of Competing Interest

None.

Supplementary material

Supplementary material associated with this article can be found, in the online version, at [10.1016/j.nxnsj.2020.100048](https://doi.org/10.1016/j.nxnsj.2020.100048).

References

- [1] Pull ter Gunne AF, Cohen DB. Incidence, prevalence, and analysis of risk factors for surgical site infection following adult spinal surgery. *Spine (Phila Pa 1976)* 2009;34(13):1422–8.
- [2] Pull ter Gunne AF, van Laarhoven CJ, Cohen DB. Incidence of surgical site infection following adult spinal deformity surgery: an analysis of patient risk. *Eur Spine J* 2010;19(6):982–8.
- [3] Fanous AA, Kolcun JPG, Brusko GD, et al. Surgical Site Infection as a Risk Factor for Long-Term Instrumentation Failure in Patients with Spinal Deformity: a Retrospective Cohort Study. *World Neurosurg* 2019;132:e514–e5e9.
- [4] Adogwa O, Fatemi P, Perez E, et al. Negative pressure wound therapy reduces incidence of postoperative wound infection and dehiscence after long-segment thoracolumbar spinal fusion: a single institutional experience. *Spine J* 2014;14(12):2911–17.
- [5] Urquhart JC, Collings D, Nutt L, et al. The effect of prolonged postoperative antibiotic administration on the rate of infection in patients undergoing posterior spinal surgery requiring a closed-suction drain: a randomized controlled trial. *J Bone Joint Surg Am* 2019;101(19):1732–40.
- [6] Yeramani S, Gum JL, Carreon LY, et al. Impact of readmissions in episodic care of adult spinal deformity: event-based cost analysis of 695 consecutive cases. *J Bone Joint Surg Am* 2018;100(6):487–95.
- [7] Payne CJ, Thomson AH, Stearns AT, et al. Pharmacokinetics and tissue penetration of vancomycin continuous infusion as prophylaxis for vascular surgery. *J Antimicrob Chemother* 2011;66(11):2624–7.
- [8] Sweet FA, Roh M, Sliva C. Intrawound application of vancomycin for prophylaxis in instrumented thoracolumbar fusions: efficacy, drug levels, and patient outcomes. *Spine (Phila Pa 1976)* 2011;36(24):2084–8.
- [9] Theologis AA, Demirkiran G, Callahan M, Pekmezci M, Ames C, Deviren V. Local intrawound vancomycin powder decreases the risk of surgical site infections in complex adult deformity reconstruction: a cost analysis. *Spine (Phila Pa 1976)* 2014;39(22):1875–80.
- [10] Martin JR, Adogwa O, Brown CR, et al. Experience with intrawound vancomycin powder for spinal deformity surgery. *Spine (Phila Pa 1976)* 2014;39(2):177–84.
- [11] Marczak D, Synder M, Sibinski M, Okon T, Kowalczewski J. The use of calcium carbonate beads containing gentamicin in the second stage septic revision of total knee arthroplasty reduces reinfection rate. *Knee* 2016;23(2):322–6.
- [12] Yarboro SR, Baum EJ, Dahners LE. Locally administered antibiotics for prophylaxis against surgical wound infection. An in vivo study. *J Bone Joint Surg Am* 2007;89(5):929–33.
- [13] McKee MD, Li-Bland EA, Wild LM, Schemitsch EH. A prospective, randomized clinical trial comparing an antibiotic-impregnated bioabsorbable bone substitute with standard antibiotic-impregnated cement beads in the treatment of chronic osteomyelitis and infected nonunion. *J Orthop Trauma* 2010;24(8):483–90.
- [14] Trujillo JM, Logue ME, Kunkel R, Demas CP. Off-label usage of absorbable beads containing antibiotics for prevention of surgical site infections. *Wounds* 2019;29(10):E84 E7.
- [15] Aiken SS, Cooper JJ, Florance H, Robinson MT, Michell S. Local release of antibiotics for surgical site infection management using high-purity calcium sulfate: an in vitro elution study. *Surg Infect (Larchmt)* 2015;16(1):54–61.
- [16] Wahl P, Guidi M, Benninger E, et al. The levels of vancomycin in the blood and the wound after the local treatment of bone and soft-tissue infection with antibiotic-loaded calcium sulphate as carrier material. *Bone Joint J* 2017;99-B(11):1537–44.
- [17] Schwab F, Ungar B, Blondel B, et al. Scoliosis Research Society-Schwab adult spinal deformity classification: a validation study. *Spine (Phila Pa 1976)* 2012;37(12):1077–82.
- [18] . Centers for disease C. Surgical site infection protocol Services USDOH; 2021.
- [19] Riley RD, Snell KI, Ensor J, et al. Minimum sample size for developing a multivariable prediction model: PART II - binary and time-to-event outcomes. *Stat Med* 2019;38(7):1276–96.
- [20] Caroom C, Tullar JM, Benton EG Jr, Jones JR, Chaput CD. Intrawound vancomycin powder reduces surgical site infections in posterior cervical fusion. *Spine (Phila Pa 1976)* 2013;38(14):1183–7.
- [21] Tubaki VR, Rajasekaran S, Shetty AP. Effects of using intravenous antibiotic only versus local intrawound vancomycin antibiotic powder application in addition to intravenous antibiotics on postoperative infection in spine surgery in 907 patients. *Spine (Phila Pa 1976)* 2013;38(25):2149–55.
- [22] Laycock PA, Cooper JJ, Howlin RP, Delury C, Aiken S, Stoodley P. In vitro efficacy of antibiotics released from calcium sulfate bone void filler beads. *Materials (Basel)* 2018;11(11).
- [23] Cooper JJ, Florance H, McKinnon JL, Laycock PA, Aiken SS. Elution profiles of tobramycin and vancomycin from high-purity calcium sulphate beads incubated in a range of simulated body fluids. *J Biomater Appl* 2016;31(3):357–65.
- [24] Stravinskas M, Horstmann P, Ferguson J, et al. Pharmacokinetics of gentamicin eluted from a regenerating bone graft substitute: in vitro and clinical release studies. *Bone Joint Res* 2016;5(9):427–35.
- [25] Oliver RA, Lovric V, Yu Y, et al. Development of a novel model for the assessment of dead-space management in soft tissue. *PLoS ONE* 2015;10(8):e0136514.
- [26] Oliver RA, Lovric V, Christou C, Walsh WR. Evaluation of comparative soft tissue response to bone void fillers with antibiotics in a rabbit intramuscular model. *J Biomater Appl* 2019;34(1):117–29.
- [27] Fleege C, Rauschmann M, Arabmotlagh M, Rickert M. Development and current use of local antibiotic carriers in spondylodiscitis: pilot study on reduction of duration of systemic treatment. *Orthopade* 2020.
- [28] von Stechow D, Rauschmann MA. Effectiveness of combination use of antibiotic-loaded PerOssal with spinal surgery in patients with spondylodiscitis. *Eur Spine Res* 2009;43(3):298–305.
- [29] Parsons JR, Ricci JL, Alexander H, Bajpai PK. Osteoconductive composite grouts for orthopedic use. *Ann N Y Acad Sci* 1988;523:190–207.
- [30] Kenna DM, Irojah BB, Mudge K, Eveler K. Absorbable antibiotic beads prophylaxis in immediate breast reconstruction. *Plast Reconstr Surg* 2018;141(4):486e 92e.
- [31] Romano CL, Logoluso N, Meani E, et al. A comparative study of the use of bioactive glass S53P4 and antibiotic-loaded calcium-based bone substitutes in the treatment of chronic osteomyelitis: a retrospective comparative study. *Bone Joint J* 2014;96-B(6):845–50.
- [32] Ferrando A, Part J, Baeza J. Treatment of Cavitary Bone Defects in Chronic Osteomyelitis: bioactive glass S53P4 vs. Calcium sulphate antibiotic beads. *J Bone Jt Infect* 2017;2(4):194–201.
- [33] Flierl MA, Culp BM, Okroj KT, Springer BD, Levine BR, Della Valle CJ. Poor outcomes of irrigation and debridement in acute periprosthetic joint infection with antibiotic-impregnated calcium sulfate beads. *J Arthroplasty* 2017;32(8):2505–7.
- [34] Turner TM, Urban RM, Gitelis S, Haggard WO, Richelsoph K. Resorption evaluation of a large bolus of calcium sulfate in a canine medullary defect. *Orthopedics* 2003;26(5 Suppl):s577–9.
- [35] Sun HJ, Xue L, Wu CB, Zhou Q. Use of vancomycin-impregnated calcium sulfate in the treatment of osteomyelitis of the jaw. *J Oral Maxillofac Surg* 2017;75(1):119–28.
- [36] Boyle KK, Sosa B, Osagie L, Turajane K, Bostrom MPG, Yang X. Vancomycin-laden calcium phosphate-calcium sulfate composite allows bone formation in a rat infection model. *PLoS ONE* 2019;14(9):e0222034.
- [37] Chang W, Colangeli M, Colangeli S, Di Bella C, Gozzi E, Donati D. Adult osteomyelitis: debridement versus debridement plus Osteoset T pellets. *Acta Orthop Belg* 2007;73(2):238–43.

- [38] Kallala R, Haddad FS. Hypercalcaemia following the use of antibiotic-eluting absorbable calcium sulphate beads in revision arthroplasty for infection. *Bone Joint J* 2015;97-B(9):1237–41.
- [39] Wahl P, Livio F, Jacobi M, Gautier E, Buclin T. Systemic exposure to tobramycin after local antibiotic treatment with calcium sulphate as carrier material. *Arch Orthop Trauma Surg* 2011;131(5):657–62.
- [40] Swieringa AJ, Tulp NJ. Toxic serum gentamicin levels after the use of gentamicin-loaded sponges in infected total hip arthroplasty. *Acta Orthop* 2005;76(1):75–7.
- [41] Ferguson JY, Dudareva M, Riley ND, Stubbs D, Atkins BL, McNally MA. The use of a biodegradable antibiotic-loaded calcium sulphate carrier containing tobramycin for the treatment of chronic osteomyelitis: a series of 195 cases. *Bone Joint J* 2014;96-B(6):829–36.
- [42] Iorio R, Yu S, Anoushiravani AA, et al. Vancomycin powder and dilute povidone-iodine lavage for infection prophylaxis in high-risk total joint arthroplasty. *J Arthroplasty* 2020;35(7):1933–6.
- [43] Murphy EP, Curtin M, Shafqat A, Byrne F, Jadaan M, Rahall E. A review of the application of vancomycin powder to posterior spinal fusion wounds with a focus on side effects and infection. A prospective study. *Eur J Orthop Surg Traumatol* 2017;27(2):187–91.
- [44] Owen MT, Keener EM, Hyde ZB, et al. Intraoperative topical antibiotics for infection prophylaxis in pelvic and acetabular surgery. *J Orthop Trauma* 2017;31(11):589–94.
- [45] Daniels AH, Bess S, Line B, et al. Peak timing for complications after adult spinal deformity surgery. *World Neurosurg* 2018;115:e509–ee15.
- [46] Pesenti S, Pannu T, Andres-Bergos J, et al. What are the risk factors for surgical site infection after spinal fusion? A meta-analysis. *Eur Spine J* 2018;27(10):2469–80.