

## Case Report

# Eggshell-like debridement and calcaneal reconstruction for managing recurrent calcaneal osteomyelitis concomitant with foot deformity: a case report

Lei Xu<sup>1,3</sup>, Bin Yu<sup>1</sup>, Yan-Jun Hu<sup>1</sup>, Guo-Xin Ni<sup>1,2</sup>, Cheng-He Qin<sup>1</sup>

<sup>1</sup>Department of Orthopaedics and Traumatology, Nanfang Hospital, Southern Medical University, 1838 Guangzhou Avenue (N), Guangzhou 510515, China; <sup>2</sup>Department of Rehabilitation Medicine, First Affiliated Hospital, Fujian Medical University, 20 Chazhong Road, Fuzhou 350005, China; <sup>3</sup>Department of Orthopaedics and Traumatology, Li Ka Shing Faculty of Medicine, The University of Hong Kong, Hong Kong, China

Received May 21, 2016; Accepted August 9, 2016; Epub December 15, 2016; Published December 30, 2016

**Abstract:** Purpose: The present study was aimed at describing a novel debridement for curing chronic calcaneal osteomyelitis, combined with distraction osteogenesis for managing consequent calcaneal deformity. Method: Our study presented a 30-year-old man with chronic calcaneal osteomyelitis, who had undergone numerous unsuccessful conventional debridement. In our institute, with systemic antimicrobial treatment his chronic calcaneal osteomyelitis was eventually cured by “eggshell-like debridement”, which indicated an extremely radical debridement to be conducted until a hollow calcaneus with only cortical bone left. Afterwards, the consequent considerable calcaneal defect and foot deformity was managed by distraction osteogenesis using Taylor Space Frame. Results: After the whole treatment, the patient was able to walk without any assistance. According to AOFAS Ankle-Hindfoot Survey, the patient’s foot function score after the treatment was much improved. Conclusion: The combination of “eggshell-like debridement” and distraction osteogenesis is very effective in managing chronic calcaneal osteomyelitis and the consequent foot deformity.

**Keywords:** Eggshell-like debridement, calcaneal osteomyelitis, foot deformity, distraction osteogenesis

## Introduction

Chronic calcaneal osteomyelitis is very hard to treat because of the small size of the calcaneus and its abundant blood supply. It can be associated with high recurrence rate and even repeated conventional debridement barely achieves a successful cure. Previous literature suggested that only radical debridement could promise an infection-free survival [1]. However, the exact extent of radical debridement is still hard to be determined. In our case, we introduce a novel concept of “eggshell-like debridement”, which is particularly effective in curing chronic calcaneal osteomyelitis, even for a patient who had underwent failed conventional debridement for more than 13 times.

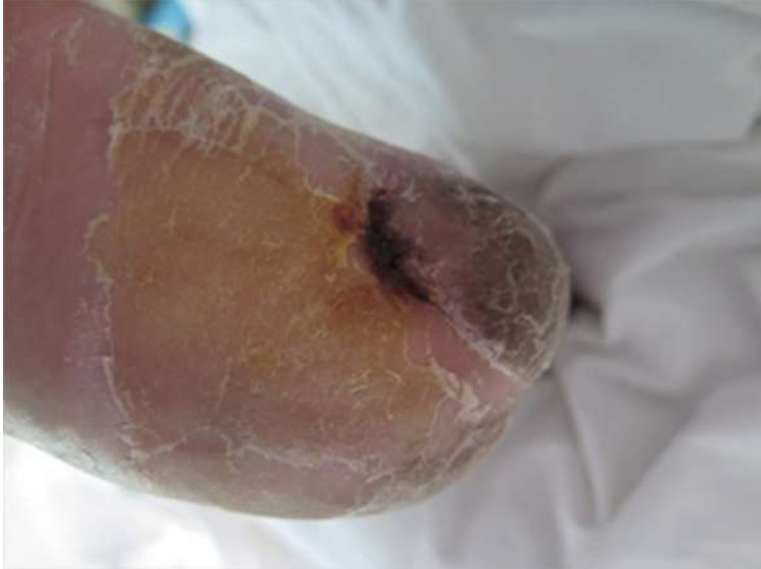In most cases, radical debridement indicates considerable bone defect of calcaneus. Several techniques, including bone graft and free fibular transportation, have been proposed to solve

the problem. These techniques are associated with unreliable consolidation and a considerable rate of complications [2]. On the contrary, distraction osteogenesis has advantage of enabling regeneration of living bone with the same length, width and strength as that of the native bone [3]. Previously only limited literature reported the experience with distraction osteogenesis in managing osteomyelitis-induced calcaneal defect [4], especially those used Taylor spatial frames (TSF) for calcaneal reconstruction.

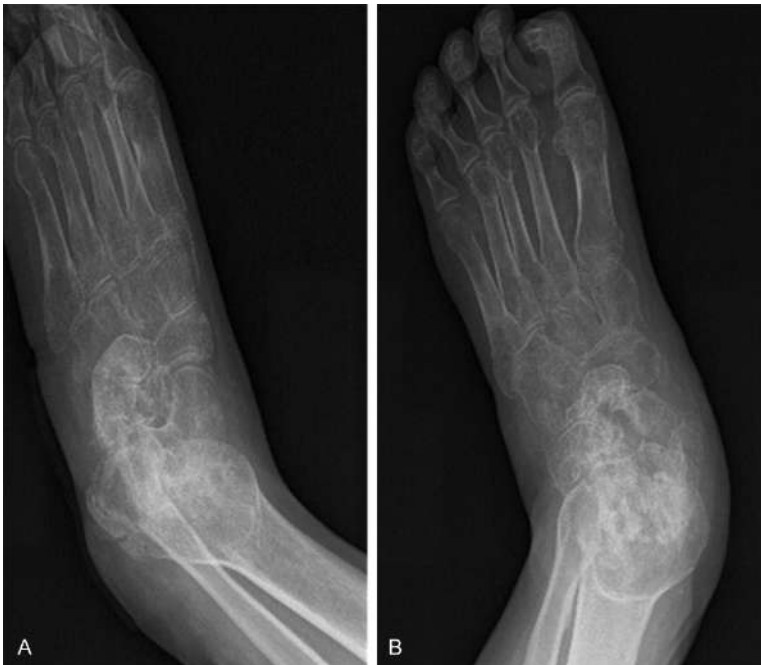## Case report

A 30-year-old man who had fallen from a 10-meter high ladder was admitted to a local hospital, where he was diagnosed with cerebral concussion, right femoral fracture and open fracture of the left calcaneus. Subsequently he received emergent treatment of cerebral concussion by neurosurgeons and plate fixation of

## A new strategy for curing calcaneal osteomyelitis



**Figure 1.** Clinical photograph of the patient upon presentation with a sinus tract.



**Figure 2.** Lateral (A) and oblique (B) radiograph of his left foot before debridement. In addition to foot deformity of equinovarus and pronation, tibiotalocalcaneal arthrodesis was also observed.

right femoral fracture. His calcaneal fracture at left foot was treated with open fracture and internal fixation after debridement. A few days later, his brain injury was cured and femoral fracture was in stable condition. However, the patient began to present with fever, fatigue and

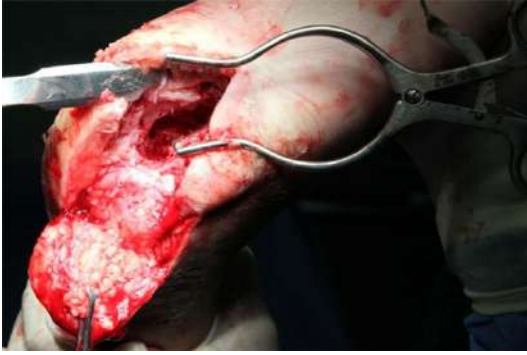malaise, with tenderness, erythema and edema at his left heel. Afterwards he was referred to a superior hospital and was diagnosed with calcaneal osteomyelitis because of *Pseudomonas aeruginosa*. According to treatment record he received systemic antimicrobial therapy and underwent debridement for 13 times at his left foot without successful cure during following several years.

Facing the deferring calcaneal osteomyelitis, the patient refused amputation and sought medical attention in our hospital. Upon inspection there was a healed surgical scar (4×3 cm) near his heel, where a sinus tract (1×0.5 cm) existed as well as necrotic debris (**Figure 1**). He was not able to move his left ankle and his left foot had deformity of equinovarus and pronation (**Figure 2**). Laboratory tests revealed erythrocyte sedimentation rate (ESR) of 31 mm/h, white blood cells (WBC) of  $17.64 \times 10^9/L$  and C-reactive protein (CRP) of 7.6 mg/L. Sinus cultures revealed the presence of *pseudomonas aeruginosa*.

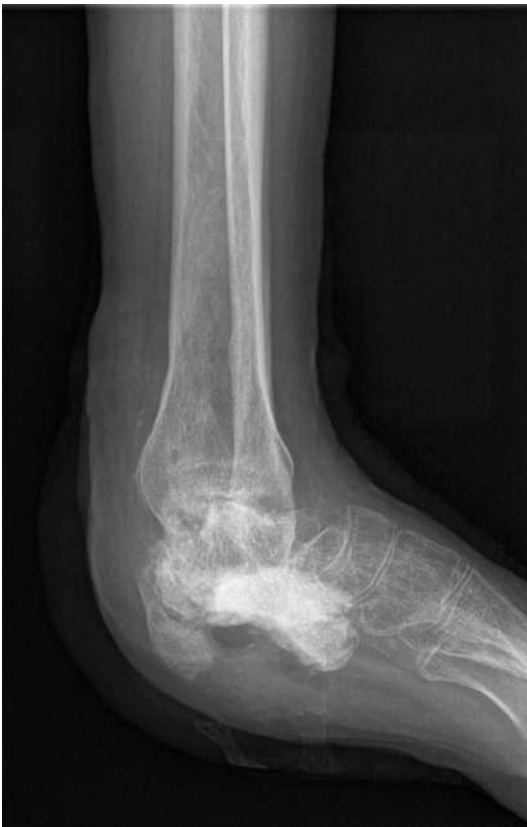In order to manage his chronic osteomyelitis and iatrogenic deformity of calcaneus, staged treatment regarding his calcaneal osteomyelitis was planned. After intravenous administration of broad-spectrum antibiotics for two weeks, the patient underwent surgery and during which

deep bone tissue samples were collected for further culture. Moreover, he received eggshell-like debridement which could be briefly introduced as follows: the infected bone, sequestrum and necrotic soft tissues were radically eliminated until the cortical inner lining was

## A new strategy for curing calcaneal osteomyelitis



**Figure 3.** The patient's calcaneus was debrided until the cortical inner lining was reached during eggshell-like debridement.



**Figure 4.** The lateral radiograph demonstrated the Stimulan® was embedded and deformity still existed after eggshell-like debridement.

reached, and debridement continued until raw bleeding was noted. Therefore a hollow calcaneus with almost only cortical bone left was made, which resembled an eggshell (**Figure 3**). After irrigation the osseous defect was then filled with vancomycin/gentamycin-impregnated calcium-sulfate (Stimulan®, Biocomposite

Ltd., UK) (**Figure 4**) and the wound incision was closed with a drain. After surgery, piperacillin was used for suppressing pseudomonas aeruginosa according to the result of culture.

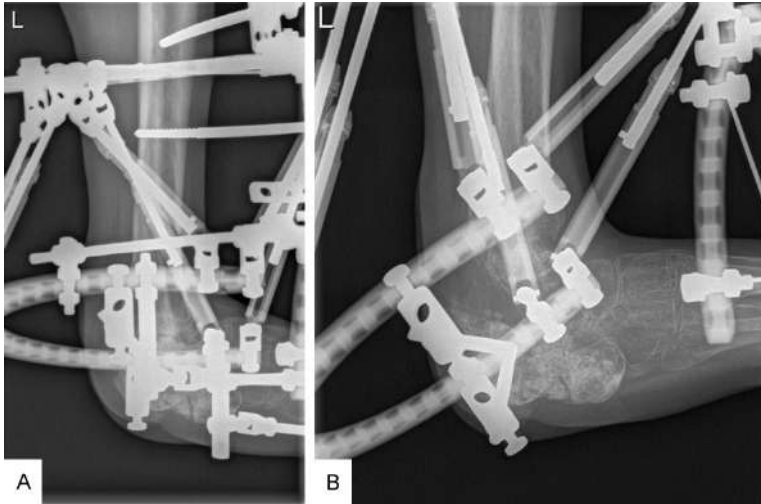
After eggshell-like debridement, the patient was regularly followed with radiographic and blood tests. After significant systemic clinical improvements (e.g. negative bacteria culture, elimination of sinus tract and purulence) were observed, he received distraction osteogenesis for calcaneal reconstruction. During operation, two hydroxyapatite-made 6-mm half pins, which were parallel and fixed on a half wire, were placed into calcaneus perpendicularly beneath the medial malleolus. Considering the tibiotalar calcaneal arthrodesis, after the talocrural joint was exposed, V osteotomy was conducted from the posterior malleolus to the distal calcaneal end as well as from the talus to the posterior calcaneus. After two ring-shaped TSF were put around lower leg, a 3/4 ring which crossed the phalanges perpendicularly was fixed to the forefoot and linked to the lower TSF by struts and rods. Subsequently two ordinary pins, perpendicular to each other as well as tibia, were fixed compressively on the proximal ring. At last a Kirschner wire was placed into the first phalange for flexion deformity correction (**Figure 5**).

One week after external fixation was installed distraction was started at a rate of 0.25 mm four times a day. The calcaneus was distracted and it totally took 50 days for distraction until contour of the calcaneus was reformed. After the removal of external fixation, physiotherapy went on for more than two months to increase the range of motion of the patient's ankle, and successively started weight-bearing practice. At 18-month follow-up, according to the AOFAS Ankle-Hindfoot Survey and physical examinations [5], the patient's foot function result of post-treatment was much higher compared with previous one (score: 74 vs. 24). Moreover, the patient regained plantigrade, pain-free foot and weight-bearing function (**Figures 6-8**).

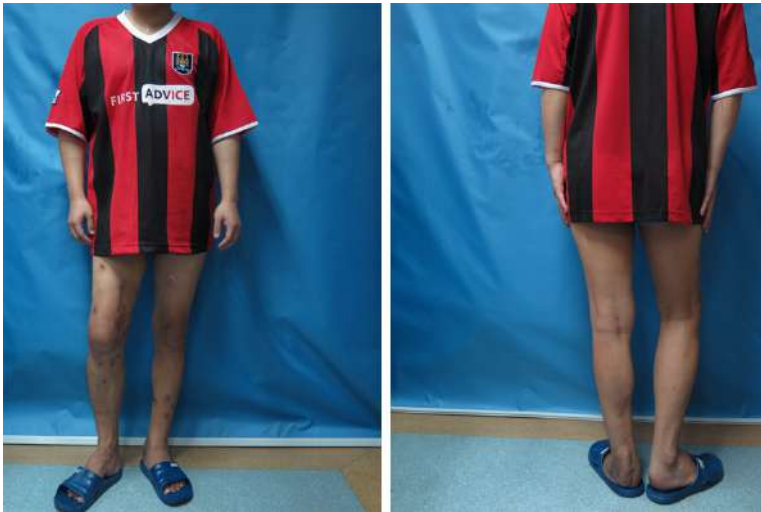### Discussion

Calcaneal osteomyelitis is difficult to treat. However, to date there is no appropriate grading system or therapeutic guideline particularly for it. On the other hand, the difficulty in its treatment may be related with the special ana-

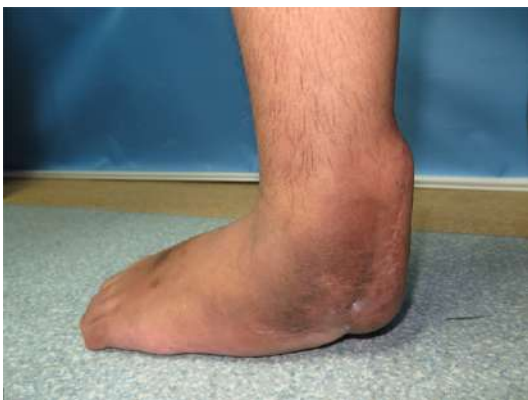## A new strategy for curing calcaneal osteomyelitis



**Figure 5.** Lateral radiographs of the external fixation on lower extremity before (A) and 4 months after (B) distraction.



**Figure 6.** The photograph of the patient approximately 2 years after the whole treatment demonstrated that the left foot of the patients had satisfactory weight-bearing function.



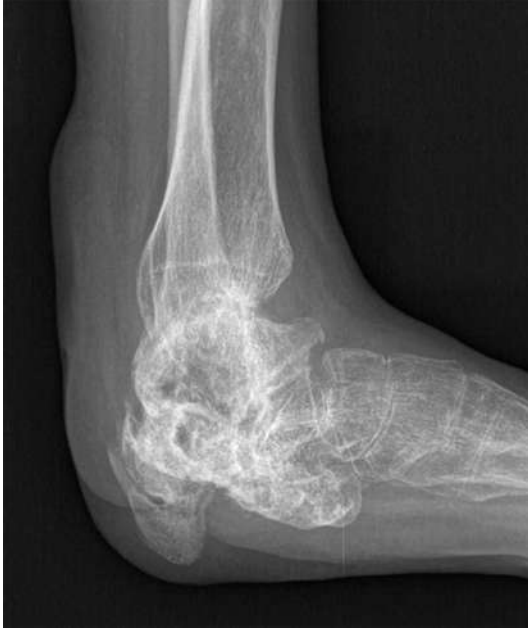**Figure 7.** The lateral photograph of the patient's left foot.

atomic features of the calcaneus. It is well known that the classical Cierny-Mader adult osteomyelitis staging system [6] has four anatomic types which include localized osteomyelitis (type III) and diffused osteomyelitis (type IV). Because of small size of the calcaneus, however, large proportion of cancellous bone and its abundant blood supply [7], localized osteomyelitis of calcaneus is easy to develop to diffused osteomyelitis. Therefore, such staging system is inappropriate for calcaneal osteomyelitis.

Debridement is the most basic treatment of calcaneal osteomyelitis, but due to the aforementioned anatomic features of the calcaneus, conventional debridement is less effective and usually leads to repeated operations. Therefore the extent of debridement in previous studies remained controversial. For example, Simpson et al. found that a wide resection 5mm beyond the apparent clearance margins would receive significant lower infection recurrence [1]. However, in the clinical practice, since the bulk of calcaneus is largely

composed of porous cancellous bone which is contained by a cortical shell, and the vascularity of calcaneus per se is beneficial for infection exchange [7], it is extremely difficult to make a clear determination on the exact boundary of "to-be-eradicated" region. Furthermore, as in our case, repeated failed debridement could make such determination even more difficult. On the other hand, there is a limitation for the raw blood as the hallmark of adequate debridement [6, 8]. Therefore, in order to reduce the risk of re-infection, we suggest eggshell-like debridement to be conducted when dealing





**Figure 8.** Compared with the **Figure 4**, the radiograph of the patient's left foot after the treatment showed the "new-forming" left calcaneus of the patient and the plantigrade foot were achieved.

with chronic osteomyelitis, especially in those who have undergone successive failures in conventional debridement.

The effect of antibiotics impregnated calcium sulfate in filling the bone defect of calcaneus has been validated in previous literature [9-11]. It has advantages of increased local concentration of antibiotics, longer antibiotic release time, osteoconductivity and absorbability [12]. Therefore, with regard to those who have undergone radical debridement (like eggshell-like debridement) the calcium sulfate is especially suitable for filling void. In our case, it not only stimulated the formation of new bone which left no further need for additional graft, but also was beneficial for suppressing the recurrent infection.

The goal of our treatment was to achieve normal calcaneus size, pain free, plantigrade and functional foot. However, eggshell-like debridement per se indicated a considerable void and the primary traumatic foot deformity. Conventional treatments to tackle these problems (e.g. bone graft and free fibular transportation) were not appropriate for our case due to the following reasons: the complete original contour of the calcaneus was lost, and its vascular

supply for bone implantation was insufficient. Moreover, bone graft was of unreliable consolidation [2] while recipient site was in poor condition, and therefore unsuitable for free fibular transportation. More importantly, such drawbacks were detrimental to maintain weight-bearing function.

Distraction osteogenesis can address the problems above, because it enables the internal fixator to attach to the very limited bone [13], and takes the most advantage of residual calcaneal bone. For example, in our case the little residual cortical calcaneus after eggshell-like debridement could not permit a calcaneal distraction by using such only limited calcaneus for pin fixation and osteotomy. Therefore, allowing for tibiotocalcaneal arthrodesis, osteotomy and distraction were conducted by utilizing part of the calcaneus, talus and distal end of tibia. Besides, a relative large docking site could simplify distraction osteogenesis and restoration of hindfoot contour. On the other hand, TSF could produce a desired correction gradually after operation since the transport rhythm and direction were both adjusted as we wanted, thus ensuring the patient was comfortable and satisfied [14]. Although the utility of TSF could be expensive, however, the alternative of increased expenses from other forms of surgeries and longer hospital stay associated with harvesting limited effect of deformity correction should be taken into consideration.

### Conclusion

For those whose calcaneal osteomyelitis does not respond to repeated conventional debridement, eggshell-like debridement can be an effective treatment. Moreover, distraction osteogenesis is recommended for traumatic deformity concomitant with bone defect to correct calcaneal deformity and restore normal ambulation.

### Disclosure of conflict of interest

None.

**Address correspondence to:** Dr. Cheng-He Qin, Department of Orthopaedics and Traumatology, Nanfang Hospital, Southern Medical University, 1838 Guangzhou Avenue (N), Guangzhou 510515, China. Tel: + (86) -20 61641741; Fax: + (86) -20 61641741; E-mail: doctorqin@163.com; Dr. Guo-Xin

## A new strategy for curing calcaneal osteomyelitis

Ni, Department of Rehabilitation Medicine, First Affiliated Hospital, Fujian Medical University, 20 Chazhong Road, Fuzhou 350005, China. Tel: + (86) -591 87981021; Fax: + (86) -591 87981022; E-mail: fgxni@graduate.hku.hk

### References

- [1] Simpson AH, Deakin M, Latham JM. Chronic osteomyelitis. The effect of the extent of surgical resection on infection-free survival. *J Bone Joint Surg Br* 2001; 83: 403-7.
- [2] DeCoster TA, Gehlert RJ, Mikola EA, Pirela-Cruz MA. Management of posttraumatic segmental bone defects. *J Am Acad Orthop Surg* 2004; 12: 28-38.
- [3] Tsuchiya H and Tomita K. Distraction osteogenesis for treatment of bone loss in the lower extremity. *J Orthop Sci* 2003; 8: 116-24.
- [4] Brinker MR, Brinker MR, Loncarich DP, Melissinos EG, O'Connor DP. Calcaneogenesis. *J Bone Joint Surg Br* 2009; 91: 662-5.
- [5] Kitaoka HB, Alexander IJ, Adelaar RS, Nunley JA, Myerson MS, Sanders M. Clinical rating systems for the ankle-hindfoot, midfoot, hallux, and lesser toes. *Foot Ankle Int* 1994; 15: 349-53.
- [6] Cierny G 3rd, Mader JT, Penninck JJ. A clinical staging system for adult osteomyelitis. *Clin Orthop Relat Res* 2003; 7-24.
- [7] Keener BJ and Sizensky JA. The anatomy of the calcaneus and surrounding structures. *Foot Ankle Clin* 2005; 10: 413-24.
- [8] Tetsworth K and Cierny GR. Osteomyelitis debridement techniques. *Clin Orthop Relat Res* 1999; 87-96.
- [9] Bibbo C and Patel DV. The effect of demineralized bone matrix-calcium sulfate with vancomycin on calcaneal fracture healing and infection rates: a prospective study. *Foot Ankle Int* 2006; 27: 487-93.
- [10] Kelly CM, Wilkins RM, Gitelis S, Hartjen C, Watson JT, Kim PT. The use of a surgical grade calcium sulfate as a bone graft substitute: results of a multicenter trial. *Clin Orthop Relat Res* 2001; 42-50.
- [11] Walsh WR, Morberg P, Yu Y, Yang JL, Haggard W, Sheath PC, Svehla M, Bruce WJ. Response of a calcium sulfate bone graft substitute in a confined cancellous defect. *Clin Orthop Relat Res* 2003; 228-36.
- [12] Beuerlein MJ and McKee MD. Calcium sulfates: what is the evidence? *J Orthop Trauma* 2010; 24 Suppl 1: S46-51.
- [13] Sella EJ. Prevention and management of complications of the Ilizarov treatment method. *Foot Ankle Spec* 2008; 1: 105-7.
- [14] Floerkemeier T, Stukenborg-Colsman C, Windhagen H, Waizy H. Correction of severe foot deformities using the Taylor spatial frame. *Foot Ankle Int* 2011; 32: 176-82.